

Sarcomatoid Carcinoma of the Gallbladder: A Case Report and Literature Review

Ting Xiong^{1,2}, Shihua Liu^{1,3}, Yuying Lei¹, Liangliang Zhang¹, Aixia Sui^{1,*}

¹Hebei General Hospital, Shijiazhuang, China

²College of Postgraduate, North China University of Science and Technology, Tangshan, China

³College of Postgraduate, Hebei North University, Zhangjiakou, China

Email address:

suiaxhebei@126.com (Aixia Sui), 1091620763@qq.com (Ting Xiong), lsh18732548669@163.com (Shihua Liu), 1265480375@qq.com (Yuying Lei), 910895582@qq.com (Liangliang Zhang)

*Corresponding author

To cite this article:

Ting Xiong, Shihua Liu, Yuying Lei, Liangliang Zhang, Aixia Sui. Sarcomatoid Carcinoma of the Gallbladder: A Case Report and Literature Review. *Cancer Research Journal*. Vol. 10, No. 2, 2022, pp. 34-37. doi: 10.11648/j.crj.20221002.13

Received: May 14, 2022; Accepted: June 2, 2022; Published: June 14, 2022

Abstract: Sarcomatoid carcinoma of the gallbladder is a highly malignant tumor originating from totipotent mesenchymal stem cells, accounting for only 4.1% of gallbladder cancers. Its clinical manifestations are very similar to adenocarcinoma of the gallbladder, mainly presenting in the digestive tract. Surgical resection is currently the only possible cure for sarcomatoid carcinoma of the gallbladder. Due to the lack of effective diagnostic means at early stage, many patients have reached the middle and late stage of diagnosis, and the prognosis is often poor. In this paper, we present a case of a 52-year-old woman with advanced and rapidly progressing sarcomatoid carcinoma of the gallbladder causing obstructive cholangitis. She developed bone marrow suppression after immunotherapy combined with chemotherapy. The patient died after symptomatic and supportive treatment. This paper reports the whole process of diagnosis and treatment in this case of gallbladder sarcomatoid carcinoma, thus carrying out a discussion based on relevant literature and providing a reference for treatment.

Keywords: Sarcomatoid Carcinoma of the Gallbladder, Diagnosis, Treatment, Obstructive Cholangitis

1. Introduction

Sarcomatoid carcinoma is a malignant tumor caused by malignant transformation of epithelial and mesenchymal tissues. Sarcoma cancers can occur in all parts of the body, but they mainly develop in the kidneys, lungs, prostate and upper respiratory tract [1]. Sarcomatoid carcinoma of the gallbladder is a rare, insidiously invasive tumor. Its clinical and imaging manifestations are not characteristic, and its treatment and prognosis are still in the exploratory stage. Surgical treatment is the preferred treatment for patients with early-stage sarcomatoid carcinoma, while radiotherapy, chemotherapy, targeted therapy and immunotherapy may help prolong survival in patients with advanced stage. At present, the study report that radiotherapy and chemotherapy can significantly improve the survival rate of patients with sarcomatoid carcinoma of the gallbladder has not been clear. In this paper, we reported a case of sarcomatoid carcinoma of

the gallbladder causing obstructive cholangitis with rapid progression to provide a reference for the diagnosis and treatment of gallbladder sarcomatoid carcinoma.

2. Case Presentation

A 52-year-old female patient was admitted with the chief complaint of upper abdominal pain accompanied by nausea and vomiting for 10 days. The patient developed upper abdominal pain, accompanied by nausea and vomiting, after eating 10 days ago. The local hospital gave symptomatic treatment, but the symptoms recurred after remission. And she presented to the emergency department of our hospital in June 2021. Physical examination noted vitals to be within normal limits with skin and sclera showed no yellow staining. But there is tenderness in her right upper abdomen, under the xiphoid process. The abdominal mass was palpable under her xiphoid process. Murphy's sign was positive, and percussion pain in the liver was positive. Emergency blood cell analysis

revealed a white blood cell count of $27.41 \times 10^9 / L$, a neutrophil percentage of 90%, and a hemoglobin (Hb) of 91 g/L. C-reactive protein was 133.78 mg/L. Prothrombin time (PT) in the four coagulation items was 13.9 seconds. She was subsequently admitted to the department of hepatobiliary surgery because of acute cholecystitis and suspicious space occupation.

After the transfer to hepatobiliary surgery, Her biochemical review showed that the total bilirubin (T-Bil), the direct bilirubin (D-Bil), the indirect bilirubin (I-Bil), the alanine aminotransferase (ALT) and the aspartate aminotransferase (AST) were $22.9 \mu\text{mol/L}$, $5.6 \mu\text{mol/L}$, $17.3 \mu\text{mol/L}$, 22.5 U/L and 36.3 U/L , respectively. Ferritin was 715.6 ng/mg in tumor markers. Ultrasound suggested the presence of stones in the gallbladder cavity, low echo mass, where blood flow signals surrounds, at the bottom of the gallbladder, and multiple swollen lymph nodes in the first hilar region and retroperitoneum. Contrast-enhanced ultrasound (CEUS) suggested a mass hypoechoic mass at the bottom of the extrahepatic gallbladder with a high possibility of malignant tumor. Abdominal CT showed thick gallbladder wall and a soft tissue mass with uneven density across the inside and outside of the gallbladder cavity. Multiple patchy low-density shadows were seen in the mass whose size is about $8.8\text{cm} \times 6.0\text{cm} \times 9.0\text{cm}$. The mass showed mild uneven enhancement on enhancement scan. The wall of the common bile duct was thickened and slightly dilated locally, with a diameter of about 11mm. There were two mass soft tissue density shadows with uneven density in gastric space and portal space, and the larger one was about $4.7\text{cm} \times 5.5\text{cm} \times 4.5\text{cm}$. On June 30, 2021, she was given a percutaneous needle biopsy of a mass. Postoperative pathological findings showed a poorly differentiated malignant tumor. Immunohistochemical results were CKpan (+), Vimentin (+), CK19 (partial +), CK7 (+). So she was diagnosed with sarcomatoid carcinoma of the gallbladder.

The patient's skin and sclera gradually became yellow. She had intermittent fever and chills with the highest temperature of 38.7°C . Reexamination of biochemical parameters and blood analysis showed elevated levels of T-Bil, D-Bil, liver

function index and infection index, and she suffered from anemia. Combined thoracoabdominal CT showed that these mass masses in the gallbladder base, hepatogastric space and portal space were enlarged. The intrahepatic and external bile ducts and the upper segment of the common bile duct were dilated, with a width of about 15mm, and the middle and lower segments of the common bile duct were narrowed. Considering the cholangitis caused by biliary obstruction, percutaneous transhepatic cholangiography and internal and external biliary drainage was performed to extract pus and blood bile. Postoperative anti-infection, fluid rehydration, upper gastrointestinal hemostasis, blood transfusion, nutritional support and other symptomatic treatment, the patient's general condition improved, bilirubin, liver function and other indicators close to normal, but infection index is still high. During this period, the following examinations were improved to guide anti-tumor therapy: 1) Positron emission computed tomography (PET/CT): gallbladder carcinoma invaded gastric antrum with multiple lymph node metastases; 2) Immunohistochemical detection of Programmed cell death-ligand (PD-L1): Tumor Proportion Score (TPS) was 90%, and Combined Proportion Score (CPS) was 91. 3) Gene detection: the tumor mutation load was high, including TP53, PALB2 and 38 individual cells. Considering the advanced sarcomatoid carcinoma of the gallbladder, biliary infection, anemia, and no chance of surgery, and combined with the results of PD-L1 immunohistochemistry and genetic testing, she was given cindillizumab 200mg combined with paclitaxel liposome 270mg on July 27, 2021. On July 30, 2021, abdominal CT showed that the mass at the bottom of the gallbladder had increased to $12.6\text{cm} \times 8.70\text{cm} \times 10.9\text{cm}$, and the larger mass in the hepatogastric space and portal space had increased to $6.9\text{cm} \times 6.9\text{cm} \times 7.8\text{cm}$. No dilation was observed in the intrahepatic bile duct and common bile duct.

After drug treatment, the patient developed grade IV myelosuppression, and was transferred to a local hospital for further symptomatic support treatment. She died on the 2nd day after discharge.

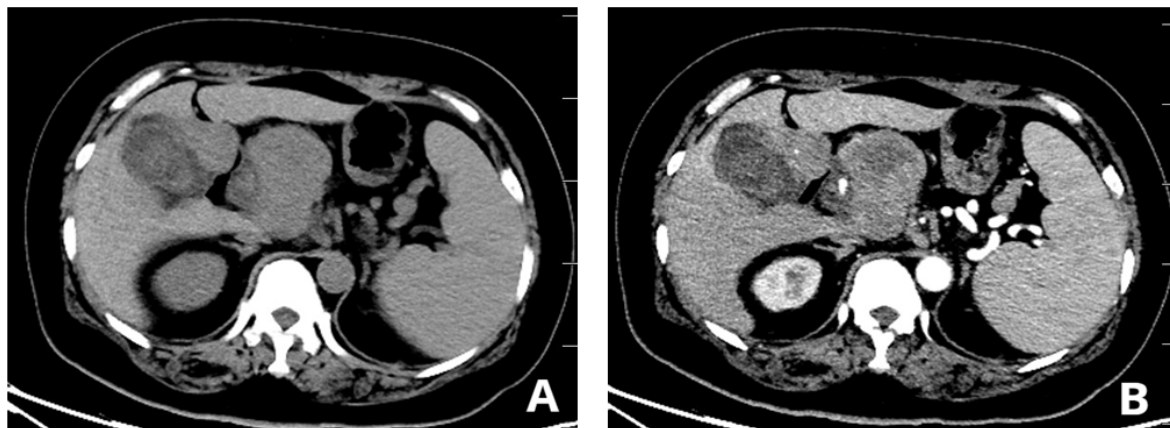


Figure 1. Abdominal CT: a mass at the base of the gallbladder and in the space between liver and stomach showed mild uneven enhancement after enhancement.

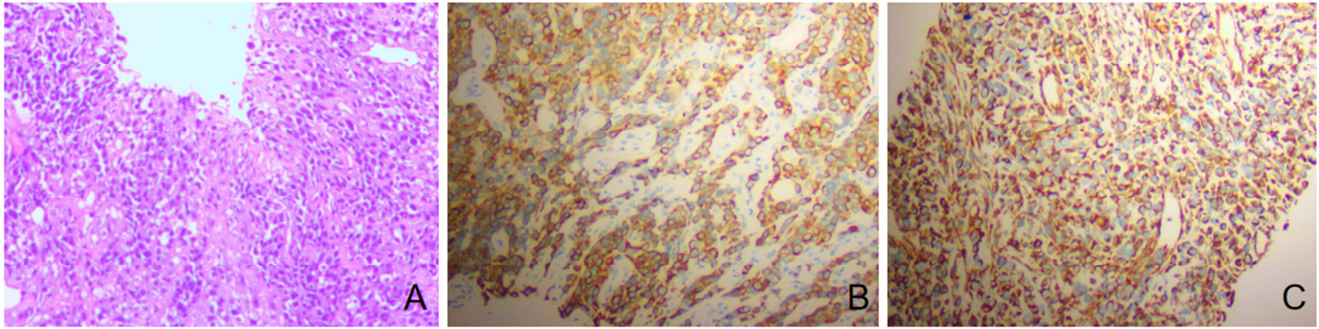


Figure 2. A: Histopathological examination (HE×100). B: Positive tumor cell marker CKpan (IHC×100). C: Positive tumor cell marker Vimentin (IHC×100).

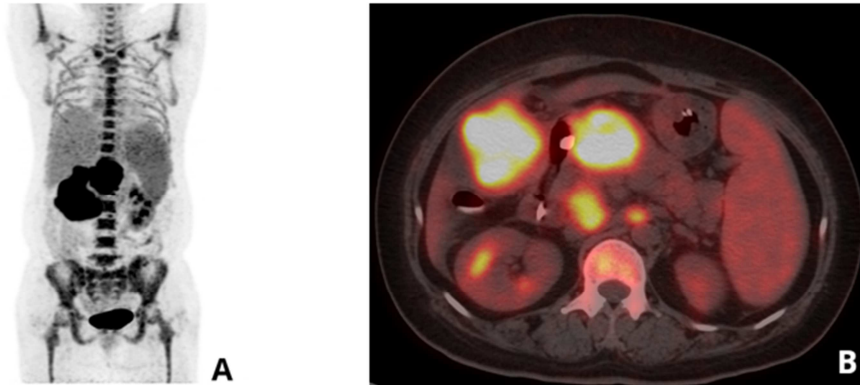


Figure 3. PET/CT: Hypermetabolic mass and multiple hypermetabolic lymph nodes at para-aortic level at both renal levels.

3. Discussion

Sarcomatoid carcinoma of the gallbladder, which is mostly seen in elderly women, is highly invasive. It develops rapidly and has a poor prognosis. Its occurrence and development may be related to gallstones [2], gallbladder polyps and estrogen [3-5]. Abdominal pain, discomfort, nausea, vomiting and jaundice are the main manifestations, which are not characteristic. Ultrasonography, CT and other imaging examinations can help diagnose benign and malignant tumors, but they cannot distinguish sarcomatoid carcinoma of the gallbladder from other gallbladder malignancies. The diagnosis mainly depends on pathological biopsy and immunohistochemical examination. Under the microscope, the tumor tissue contained two kinds of epithelioid components and sarcomatoid spindle cell components, or no epithelioid components, and the morphology was similar to spindle cell sarcoma but actually was carcinoma [6, 7]. Immunohistochemical examination showed positive markers of epithelial origin, like CK and EMA, and mesenchymal origin, like Vim and SMA, in spindle cell components [8-10]. In this case, upper abdominal pain, nausea and vomiting were the main manifestations of admission, and upper abdominal tenderness and Murphy's positive signs were present. Imaging examination can confirm malignant gallbladder space and lymph node metastasis in hepatogastric space and portal space. Under histopathological biopsy, the fusiform of cancer cells was not obvious, but the two tissue markers of epidermal origin (CKpan, CK19, CK7) and mesenchymal

origin (Vimentin) were positive, which were similar to previous reports, indicating that sarcomatoid carcinoma of the gallbladder could be clearly diagnosed.

At present, patients with sarcomatoid carcinoma of gallbladder are mainly treated with radical surgery, followed by chemotherapy. The survival time of patients undergoing radical surgery was significantly longer than that of patients undergoing palliative surgery, including cholecystectomy alone and bile drainage after tumor obstruction [11]. The patient in this case had advanced tumor, poor general condition and no chance of surgery. Pd-l1 immunohistochemical and genetic tests can provide a more individualized diagnosis and treatment. By expressing PD-L1, tumor cells bind to Programmed cell death (PD-1) on the surface of T cells to induce apoptosis or inhibition of tumor-specific T cells and weaken the anti-tumor effect of the immune system [12-14]. Pd-1 /PD-L1 inhibitors can enhance the anti-tumor effect of the immune system. Gene detection can find the application target of targeted drugs and show the strength of tumor mutation load, and a higher tumor mutation load indicates better immunotherapy effect [15]. In this case, PD-L1 test was positive, 38 individual cells including TP53 and PALB2 were mutated, and tumor mutation load was high. TP53 is a tumor suppressor gene involved in cell cycle control and genome integrity preservation [16], and PALB2 mutation carriers have a shorter overall survival than non-carriers [17]. For these two mutated genes, no relevant targeted drugs are currently on the market. Combined with the above test results, the patient was given PD-1 inhibitor combined with chemical therapy, but due to the rapid

progression of the disease and the occurrence of grade IV myelosuppression, the efficacy of this treatment was not significant.

In this case, the patient progressed very quickly, with the time from onset of discomfort to death less than 2 months. Repeated CT scans during hospitalization showed that the tumor continued to increase, and the tumor increased by about 5cm in 40 days, resulting in bile duct obstruction and cholangitis. The primary treatment for obstructive cholangitis is to remove the obstruction as soon as possible. If not timely treatment, the pressure in the bile duct will further increase, and the bacterial infected bile will enter the capillaries of the liver, leading to hematologic infection, sepsis, and even septic shock [18]. In this case, percutaneous transhepatic biliary drainage was performed to drain the pus and blood bile. After relieving the pressure in the bile duct, the patient's bilirubin and liver function indexes gradually approached normal, but the white blood cell count and neutrophil percentage. It was considered that there was still biliary infection, and pulmonary infection and tumor-induced abdominal infection were not controlled.

After infection, the body rapidly and massively produces granulocytes to complete the defense response [19]. However, long-term infection could make bone marrow hematopoietic fatigue, which may be one of the reasons for severe bone marrow suppression in this patient after chemotherapy. At the same time, bone marrow suppression can inhibit and weaken the ability of the body to fight infection, further aggravating the progress of the disease.

4. Conclusions

Sarcomatoid carcinoma of the gallbladder has a high degree of malignancy, rapid progression, and the possibility of rapid death. Imaging examination is difficult to determine the nature of the tumor. Therefore, clinical vigilance should be raised, and pathological biopsy and immunohistochemical examination should be performed when necessary. Radical surgery is the first treatment, and PD-L1 immunohistochemical test and gene test can guide the formulation of more individual diagnosis and treatment plan. Predrug infection may be one of the reasons for severe bone marrow suppression in tumor patients after chemotherapy.

References

- [1] Shi Y, Chen J, Chen H, et al. Sarcomatoid carcinoma of the gallbladder: a case report. *J Int Med Res.* 2020, 48 (6): 300060520935283.
- [2] Hamdani N H, Qadri S K, Aggarwalla R, et al. Clinicopathological study of gall bladder carcinoma with special reference to gallstones: our 8-year experience from eastern India [J]. *Asian Pac J Cancer Prev*, 2012, 13 (11): 5613-5617.
- [3] Hundal R, Shaffer E A. Gallbladder cancer: epidemiology and outcome [J]. *Clin Epidemiol*, 2014, 6: 99-109.
- [4] Siddiqui Mehdi, Hegde Sheetal, Nguyen Tung, et al. Sarcomatoid carcinoma of the gallbladder: A rare form of gallbladder cancer. *SAGE open medical case reports.* 2020, 8: 2050313X20906739.
- [5] Song X, Hu Y, Li Y, et al. Overview of current targeted therapy in gallbladder cancer. *Signal Transduct Target Ther.* 2020, 5 (1): 230.
- [6] He Q Q. Clinicopathological and prognostic analysis of sarcomatoid carcinoma of digestive system [D]. Zhengzhou University Internal Medicine (Gastroenterology), 2017.
- [7] Toledo PF, Berger Z, Carreño L, et al. Sarcomatoid carcinoma of the pancreas - a rare tumor with an uncommon presentation and course: A case report and review of literature. *World J Clin Cases.* 2021, 9 (15): 3716-3725.
- [8] Li X P, Zhu C Y, Liu S L, et al. Diagnosis and treatment of sarcomatoid carcinoma of gallbladder: a report of 4 cases [J]. *Hepatobiliary and pancreatic surgery*, 2020, 32 (05): 307-309.
- [9] Qin Q, Liu M, Wang X. Gallbladder sarcomatoid carcinoma: Seven case reports. *World J Clin Cases.* 2020, 8 (17): 3881-3889.
- [10] Feng F, Cheng Q, Yang L, et al. Guidance to rational use of pharmaceuticals in gallbladder sarcomatoid carcinoma using patient-derived cancer cells and whole exome sequencing [J]. *Oncotarget*, 2017, 8 (3): 5349-5360.
- [11] Hu Z H, Li Z W, Shen L, et al. Surgical therapy and prognosis of sarcomatoid carcinoma of the gallbladder [J]. *Hepatobiliary Pancreat Dis Int*, 2010, 9 (2): 175-179.
- [12] Zou W, Wolchok J D, Chen L. PD-L1 (B7-H1) and PD-1 pathway blockade for cancer therapy: Mechanisms, response biomarkers, and combinations [J]. *Sci Transl Med*, 2016, 8 (328): 324r-328r.
- [13] Chamoto K, Al-Habsi M, Honjo T. Role of PD-1 in Immunity and Diseases [J]. *Curr Top Microbiol Immunol*, 2017, 410: 75-97.
- [14] Sun L, Li CW, Chung EM, et al. Targeting Glycosylated PD-1 Induces Potent Antitumor Immunity. *Cancer Res.* 2020, 80 (11): 2298-2310.
- [15] Song Z Q, Guo G F, Zhu Y M, et al. A case of super advanced sarcomatoid lung cancer induced by parbrizumab [J]. *Chin J Clin Lung*, 2022, 27 (01): 150-153. 2022, 27 (01): 150-153.
- [16] Bykov V J, Issaeva N, Shilov A, et al. Restoration of the tumor suppressor function to mutant p53 by a low-molecular-weight compound [J]. *Nat Med*, 2002, 8 (3): 282-288.
- [17] Deng M, Chen H H, Zhu X, et al. Prevalence and clinical outcomes of germline mutations in BRCA1/2 and PALB2 genes in 2769 unselected breast cancer patients in China [J]. *Int J Cancer*, 2019, 145 (6): 1517-1528.
- [18] Yi F. Clinical effect of ERCP in the treatment of acute obstructive suppurative cholangitis [J]. *Contemporary medicine*, 2021, 27 (32): 168-169.
- [19] Ye Y, Huang R, Dai Y. Immunomodulatory effects of neutrophils in the state of homeostasis and pathology [J]. *Journal of ling nan emergency medicine*, 2020, 25 (03): 319-320.